

5-1-1932

Idiopathic aplastic anemia

Lowell C. Barr
University of Nebraska Medical Center

This manuscript is historical in nature and may not reflect current medical research and practice. Search [PubMed](#) for current research.

Follow this and additional works at: <https://digitalcommons.unmc.edu/mdtheses>



Part of the [Medical Education Commons](#)

Recommended Citation

Barr, Lowell C., "Idiopathic aplastic anemia" (1932). *MD Theses*. 585.
<https://digitalcommons.unmc.edu/mdtheses/585>

This Thesis is brought to you for free and open access by the Special Collections at DigitalCommons@UNMC. It has been accepted for inclusion in MD Theses by an authorized administrator of DigitalCommons@UNMC. For more information, please contact digitalcommons@unmc.edu.

IDIOPATHIC APLASTIC ANEMIA

By

LOWELL C. BARR.

Senior Thesis--1932.

TABLE OF CONTENTS.

- I. INTRODUCTION AND CASE REPORT.
- II. DEFINITION AND CLASSIFICATION.
- III. HISTORY.
- IV. AETIOLOGY.
- V. MORBID ANATOMY.
- VI. SYMPTOMS.
- VII. PHYSICAL EXAMINATION AND LABORATORY FINDINGS.
- VIII. DIAGNOSIS.
- IX. PROGNOSIS.
- X. TREATMENT.
- XI. SUMMARY AND CONCLUSIONS.
- XII. BIBLIOGRAPHY.

480297

IDIOPATHIC APLASTIC ANEMIA

by
L.C. Barr.

I-Introduction and Case Report.

During the past year, a very interesting case of aplastic anemia of the idiopathic type, occurred in the University Hospital. Since it is so rarely seen, it was decided to make a general review of the literature and draw up a resumé including the history, etiology, pathology, diagnosis and any treatment, which might prove valuable in this condition. Due to the fact that it is reported so infrequently, does not rule out the possibility that, it may occur in a mild or chronic form, which by careful study might be detected. Also it may occur combined with various diseases and not be recognized, if one is not familiar with the more characteristic manifestations which are usually displayed.

The following case report is not complete due to insufficient early history and laboratory data which was not done, but there is sufficient data to indicate an aplastic anemia and the autopsy findings confirm the diagnosis.

The following case conforms to the so-called aplastic type of blood disorder of unknown etiology. This condition probably occurs much more frequently, than it is reported.

M. L., female, age 7, American was apparently well until March, 1931. In the middle of March, she became some what pale and anemic in appearance. She was troubled occasionally with a slight irregular epistaxis. Following the extraction

IDIOPATHIC APLASTIC ANEMIA

by
L.C. Barr.

of an aching tooth, she was troubled with a moderate hemorrhage from the socket for three days. Later she developed an epistaxis which has persisted irregularly since. She was under a doctor's care at home for one month and due to no improvement was sent to a local hospital. Three weeks after the tooth extraction, the mother noticed black bowel movements. She was removed to a Grand Island hospital on April 26th, and while there she received three indirect transfusions with no marked improvement. While in the Grand Island hospital she developed a bilateral swelling of the face which was diagnosed mumps. After ten days this disappeared. She was in bed constantly. The last transfusion was given the 15th of May and the preceding one on May 6th. She was brought to the University Hospital June 4, 1931.

Past History: Essentially negative. She had always been a healthy child with no history of Rheumatic fever nor any blood disorder.

Family History: Father-age 47-living and well. Mother-age 41-living and well. Sisters, 4, living and well, and Brothers, 3, living and well. No carcinoma, tuberculosis, nor known blood diseases in the family.

Physical Examination: White girl, 7 years of age, very pale and apathetic. She has a pack in the left nostril for hemostasis and bandages about each elbow. She appears

IDIOPATHIC APLASTIC ANEMIA

by
L.C. Barr.

very weak.

Eyes: Pupils large and react to light and accommodation.

Ears: Drums pale but reflect light, no discharge.

Nose: Pack in the left side.

Throat: Tonsils hypertrophied and pale. There is an inflammatory area between the uvula and the left tonsil; it appears to be the site of a spurious hemorrhage.

Tongue: Pale, coated, foul breath.

Teeth: In good repair.

Chest: Negative.

Heart: Rapid rate (120). Peculiar first sound (split), with a gallop rhythm. P₂ markedly accentuated. P.M.I. out farther than normal, and easily palpable.

Abdomen: Soft and flat; liver and spleen not palpable. (Spleen later found to be palpable.)

Extremities: No edema; knee jerks present; definite bilateral exhaustible clonus; other sensory findings were normal.

Glands: Slight cervical adenopathy.

Laboratory: (Grand Island report).

Hgb. 20 to 30%; R.B.C. 1 million--platelet count 70,000.

Urine: essentially negative on June 4 and 12.

Blood Findings:

(As per chart--next page).

IDIOPATHIC APLASTIC ANEMIA
by
L.C. Barr.

Blood findings:

Date	6-5-31	6-8	6-9	6-10	6-12	6-13	6-15	6-16	6-17
Hgb	20%	45%		28%	28%	14%	20%	12%	8%
R.B.C.	1,130	2,200		2,090	1,350	840	1,300	650	500
Leucocyte	1400			1600	2000	1300	1400	1500	2200
Coag. tim	Ear	2 min							
Baso	0								
Eosin	0						1	1	
Youngs	4	No Nucleated Red Cells seen	3	3	5	6	3	5	2
Staphs	8		9	10	5	10	2	4	6
Segment	8		2	13	4	5	13	4	11
Monos	4		4	5	3	4	4	4	3
Lymphs	76		76	62	68	67	70	70	63
Blasto	2		3	2	2	4	2	5	4
Myelo			3	4	3	4	3	4	2
Turck				1			2	2	
Reider								1	
Unidentified									

June 5, Slight anisocytosis, no poikilocytosis.

Bleeding time---20 minutes.

Platelet count (Wright) 28,000--(Schilling) 18,000.

June 5, Reticulocyte count 0.3%.

June 6, Type III---Jansky.

June 9, Platelet count, 48,000.

June 13, Platelet count, 64,000.

Blood culture, negative after 64 hours.

June 17, Blood culture, negative after 13 days.

Treatment: General diet.

Beginning June 6, liver extract, 1 ampoule, b.i.d.

June 6, 400cc citrated blood.

June 13, 250cc. citrated blood.

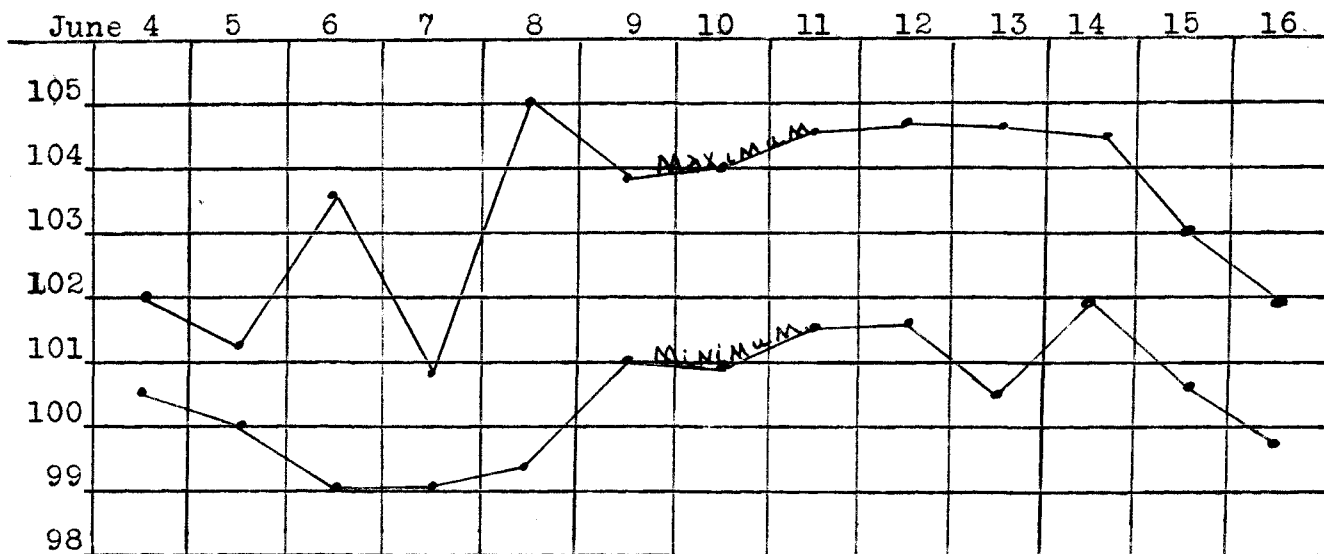
June 14, Normett's solution 5cc every other day.

June 16, Ventriculin $m_x v$, t.i.d. \bar{c} meals.

IDIOPATHIC APLASTIC ANEMIA

by
L.C. Barr.

Temperature Curve.

History of Progress:

- June 6, 1931--Marked oozing from needle wound in arm following transfusion.
- June 7, 1931--Condition somewhat improved.
- June 11, 1931--Complains of pain in left inguinal region with no apparent cause.
- June 13, 1931--Patient very pale and restless--transfused.
- June 15, 1931--Dr. Hunt advises against deep roentgen radiation due to anemia and general weakened condition.
- June 17, 1931--Hemoglobin 8%. Patient died this P.M.

IDIOPATHIC APLASTIC ANEMIA

by
L.C. Barr.

AUTOPSY REPORT: (Pathologists, Drs. Eggers, Weinberg, Norall).
(Autopsy performed 6-17-31. 7 P.M.)

External Examination: Body is that of a young girl of about stated age, well developed and well nourished. The skin is of a waxy pale color. There are a few petechial hemorrhages, two to four millimeters in diameter, over trunk and extremities.

Peritoneal Cavity: The subcutaneous abdominal fat was about normal thickness. There is blood in the intestinal wall as shown by the black discolored areas. The stomach is distended and the liver extends to the costal margin.

Thorax: Thymus is of normal size. The blood is taken from the heart for a blood culture and it is very pale and of a watery consistency. (Culture found negative).

Heart and pericardium; normal amount of pericardial fluid. The heart weighs 200 grams. Petechial hemorrhages over the heart. There is a natural hypertrophy of the left ventricle. Valves are normal. Coronary arteries are patent.

Right lung; weighs 170 gms. It is crepitant throughout. Cut section shows a marked pallor. There is a little congestion posteriorly. There is a brown discoloration in a few localized areas as if it were due to an old hemorrhage.

IDIOPATHIC APLASTIC ANEMIA

by
L.C. Barr.

Left lung; Weighs 110 gms. Description the same.

Abdomen: Liver weighs 780 grams. Gall bladder is distended, and shows hemorrhage into the wall. There is a green-gray-red color seen on the surface of the gallbladder. The wall is of normal thickness. The liver is pale and on cut section, a watery fluid oozes from the tissue. It appears to be relatively large in size.

Right adrenal; slightly enlarged.

Spleen; weighs 60 grams. There are adhesions to the parietal wall. There is hemorrhage near the spleen. Has less than the normal pigmentation and is rather pale.

Right kidney; Weighs 120 grams. There are petechial hemorrhages on the surface. On cut surface it is very pale, and it is difficult to distinguish between medullary and cortical portions.

Left kidney; Weighs 120 grams. Description same.

Bone Marrow: Taken from the middle of the right femur. It is of a pale yellow fatty consistency.

MICROSCOPICAL EXAMINATION:

Heart: One section of the heart is rather poorly preserved. The fibres give the appearance of being evacuated and the nuclei are either pycnotic or markedly swollen. The pericardium and endocardium show no particular changes.

IDIOPATHIC APLASTIC ANEMIA

by
L.C. Barr.

Lung: There are no areas of consolidation found in the lung; alveoli are well preserved except in one small area where they suggest emphysema. A section thru the bronchus shows a number of areas of mononuclear infiltration in the submucosa. The glands are not unusual in appearance.

Liver: A section of the liver shows nothing unusual. The central veins are not enlarged and the liver cords are in good condition. Portal spaces show a very slight cellular infiltration.

Spleen: Capsule is thin and shows nothing unusual. Trabeculi are present in about the usual size and number. Malpighian corpuscles are moderate in size and the germinal centers show a moderate degree of activity. An occasional germinal center is found to be represented by a mass of large and rather pale staining cells, and a good deal of unorganized fibrillary material. The reason for this reaction is difficult to make out for these do not have the appearance of the ordinary phagocyte cells, and no areas of similar activity are found outside the Malpighian corpuscles. There are, however, a moderate number of phagocyte cells scattered throughout the splenic pulp. No granulocytes are seen.

Pancreas: A section of the pancreas shows nothing unusual.

IDIOPATHIC APLASTIC ANEMIA

by
L.C. Barr.

The secreting acini are fairly well preserved and the islands are present in adequate numbers.

Kidney: The glomeruli in each are well preserved, although a number of them contain casts and amorphous debris. The blood vessels show nothing unusual.

Adrenals: The cortex and medulla are well differentiated. Lipoid bearing cells are present in considerable numbers. There is no hemorrhage to be seen.


Bone: The tissue is decidedly aplastic. There are only a few cell groups, otherwise the marrow is entirely fatty. All the cells are reticulum cells, hemoblasts and numerous very large macrophages which contain pigment. Many of the hemoblasts are degenerative in appearance. Transitoid stages between these and the large macrophages are seen often. There is no evidence of development of myeloid cells. The appearance suggests that some severe toxin paralyzed the marrow and brought about the macrophage formation.

(Marrow dictated by Dr. John S. Latta).

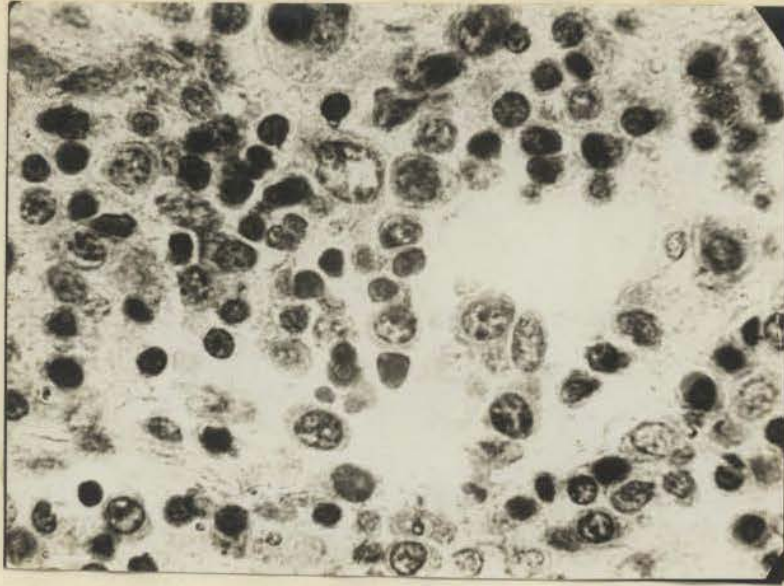
DIAGNOSIS: APLASTIC ANEMIA OF UNKNOWN ORIGIN.

The following photographic prints were taken from sections of the bone marrow ^{contributed} and through the kindness of Dr. Latta. As demonstrated by the picture, there is distinct fatty degeneration of the bone marrow. Normally in an individual, seven years of age, the marrow should be of the pinkish-red type, without fatty infiltration. Dr. Latta states that the marrow, as demonstrated by the sections and pictures appears to be suffering from a severe toxemia.

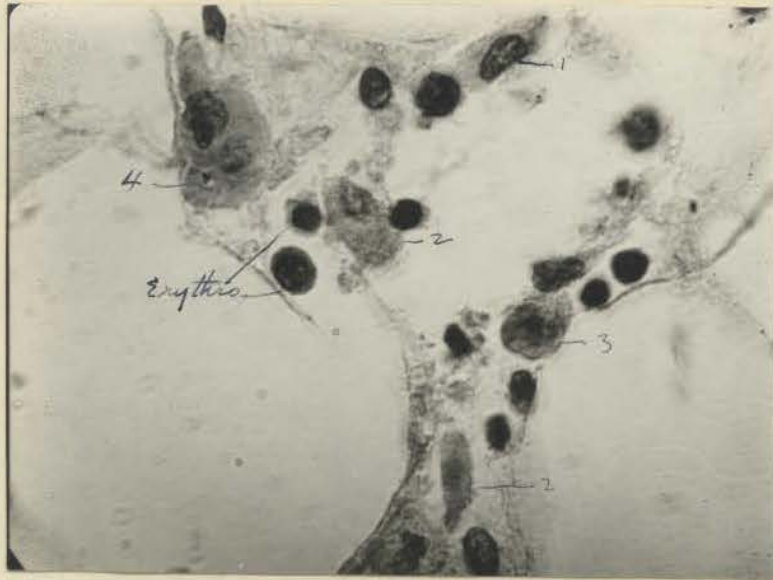
The doctor, who visited the patient first, following the extraction of the tooth was quite certain that she carried a fairly high temperature, which might indicate a possible aetiological factor in the production of the severe toxemia.



Low power



High power



High power

1,2,3,4, represent various stages in the degree of toxicity in the hemoblastic cells. Erythro. or immature erythrocytes.

IDIOPATHIC APLASTIC ANEMIA

by
L.C. Barr.

II-DEFINITION AND CLASSIFICATION.

According to Gibson⁸, the term "aplastic anemia" is not that of a disease but rather an anatomical type of disorder of the blood forming organs. It is a condition in which every trace of reaction and transformation of the bone marrow is wanting. As suggested by Ordway and Gorham¹⁹, this form of anemia differs from pernicious anemia and the usual secondary anemias, in that the red cells and other elements are greatly reduced in number, and no nucleated forms are found to suggest active marrow function. There are now many reports of similar cases of profound and rapidly progressive anemia, usually occurring in young adults, for which no cause has yet been discovered. This is the type of dysfunction with which we are concerned chiefly. Such cases are often referred to as primary, idiopathic, or cryptogenic aplastic anemia. Cases with clinical pictures and blood findings quite indistinguishable from primary aplastic anemia, but for which definite causal factors are found, are termed secondary aplastic anemia.

Duke⁵ has divided aplastic anemia into four clinical types, one in which there is a reduced rate of blood formation, and one in which there is an increased rate of blood destruction. His third type of so called aplastic anemia is that which occasionally occurs as a terminal event in the course of pernicious anemia; the blood picture resembles aplastic anemia

IDIOPATHIC APLASTIC ANEMIA

by
L.C. Barr.

in the scarcity of red cells, granulocytes, and platelets, but differs in the showing at autopsy a megaloblastic marrow instead of a fatty marrow. The fourth type has been well named myelophthisic anemia in which the usual bone marrow elements are thought to be crowded out by foreign cells, as in aleukemic leukemia.

IDIOPATHIC APLASTIC ANEMIA.
L.C. Barr.

III-HISTORY.

In 1888 Ehrlich⁶ described the blood and autopsy findings of a peculiar type of anemia occurring in a patient in the Gerhardt Clinic, which he designated aplastic anemia. A brief review of this case report is as follows:

1. Ehrlich⁶; female, age 21 years, first symptoms metrorrhagia for eighteen days before onset. Red cells 213,360. White cells in proportion of 1:1000 red cells. Hemoglobin, very low. Lymphocytes, 80%. Polymorph neutrophiles 14%. Little poikilocytosis; no nucleated red cells. Bone marrow yellow, slightly pink in the diaphyses; Very few normoblasts and myelocytes. Duration thirty days with death terminating.

Schneider²⁴ states that aplastic anemia has been reported between the ages 5.7 years and 68 years. It is more frequent in early adults and more common in females, in the proportion of 20:15. It runs a course of from two weeks to two and one-half years, the average being six months.

Smith²⁶ reviewed sixty-five cases and his summary shows that thirty-one were males, thirty-one females, and three were unspecified. The average age of sixty-one of the patients was twenty-nine and one-half years, the youngest being two years and the oldest sixty-eight years. The average duration

IDIOPATHIC APLASTIC ANEMIA.

by
L.C. Barr.

of the disease in fifty cases was three months, the shortest four days, and the longest one and one-half years.

Minot¹⁶ says that it occurs particularly in individuals between fifteen and thirty years, and females are perhaps more susceptible than males.

According to Carey and Taylor², who have estimated with reasonable accuracy, not over one-hundred-fifty cases of primary aplastic anemia have been reported so far. A few cases reported among children were obviously anemias of hemorrhagic and aplastic type, following directly as a result of severe infections.

Scheard²⁵, in his monograph on pernicious anemia and aplastic anemia, has covered the bibliography up to 1923, and discovered one-hundred-twenty-five authentic cases. According to Carey and Taylor², since 1923 about twenty cases have been reported. Schneider²⁴ mentioned sixty cases found up to 1918.

Root²², in reviewing the literature since 1918, found twenty additional cases. In 1914, Musser¹⁷ collected fifty-nine authentic cases and added one. Symmers²⁹ reported in 1917, three cases in five-thousand-six-hundred autopsies at the Bellevue Hospital.

During the interval between January 1, 1920 and January 1, 1932 approximately fifty-four thousand patients were treated in the University Hospital³³, and only two cases have been diagnosed aplastic anemia--and these occurred during the past

IDIOPATHIC APLASTIC ANEMIA.

by
L.C. Barr.

year. Also, during the same period, there were one-hundred-four cases of pernicious anemia out of a total of one-hundred-fourteen primary anemias. There were forty-six cases of secondary anemia, plus seventeen unclassified anemias. Also during the same period there were twenty-two cases of leukemia.

Considering the difficulty in diagnosis and the variation in the symptoms, very likely a good many cases have gone misdiagnosed or undiagnosed.

The depressed function of the bone-marrow is emphasized by the following terms which have been proposed for this type described by Ehrlich⁶; "aleukia hemorrhagica" by Frank⁷; "hemolytic aplastic anemia" by Türk³⁰; "aregeneratory anemia" by Pappenheim²⁰; "anemia gravis" by Hirschfeld¹⁰; "toxic paralytic anemia" by Schneider²⁴; and "hypoplastic anemia" suggested by Scheard²⁵. Agnew¹ feels that ultimately idiopathic aplastic anemia may be divided into a hemolytic type with marrow exhaustion or paralysis and a marrow deficiency type similar to the a-regeneratory anemia of Pappenheim²⁰.

IDIOPATHIC APLASTIC ANEMIA.

by
L.C. Barr.

IV-ETIOLOGY.

As the term "idiopathic aplastic anemia" signifies, the causative factor or factors are unknown. The etiology of secondary aplastic anemia is known, as stated before, and there are many different factors which may enter in. The clinical and pathological pictures may be identical. Such an aplasia of the bone marrow may occur as a terminal event in pernicious anemia. For want of a better explanation, Upham and Nelson³¹ consider it due to a fatigue of the bone marrow. Symmers²⁹ thinks that the relationship between aplastic anemia and pernicious anemia is "one of variation in the response of the body to the same cause". According to Minot¹⁶, a tendency in the direction of reduced blood generation may be observed occasionally in persons who have intestinal parasites, metallic poisoning, neoplasms, endocrine disturbance, pregnancy, chronic gastro-intestinal disease, toxemia as a result of kidney disease, excess radium or roentgen radiation, liver cirrhosis, chronic infections, or defective diet. Inanition was demonstrated by Doan³, and Sabin²³ to be a causative factor in their experiments on pigeons in which an aplasia was produced following simple starvation. Duke⁴ observed a case of chronic aplastic anemia, which seemed analagous to Doan's experimental condition in an adult whose stomach, because of a developmental abnormality, scarcely larger than that of a twelve year old child. He had

IDIOPATHIC APLASTIC ANEMIA.

by
L.C. Barr.

never been able to tolerate normal quantities of food, and at the time he was observed he had been living on a deficient diet for many years. The administration of a concentrated diet rich in liver and vitamins gave rise to a very rapid recovery, in fact he was changed from an almost moribund patient with a classic blood picture of aplastic anemia to one of good health, within a period of two months.

"For the purpose of determining whether anemia of the progressive type was due to a deficient compensation upon the part of bone marrow for losses incurred through infectious diseases, Levi¹³ tested the erythroblastic function of the marrow in dogs by administration of doses of from twenty to thirty centigrams of pyrocin, thus obtaining at the end of a month severe anemia, in which the red corpuscles were reduced one-half and even two-thirds, but on continued administration of the same dose, an increase in number of the corpuscles to approximately one-half of the normal occurred, and the figure then remained stationary. When experiments were discontinued and the number permitted to return to normal, the same dose was again administered, the substance no longer possessed hemolytic power, which indicated that the red corpuscles had acquired a certain resistance or degree of immunity against pyrocin. Where larger doses were given later, anemia returned and the animals succumbed. At this stage no improvement was effected by discontinuance of experiments. Thus it was

IDIOPATHIC APLASTIC ANEMIA

by
L.C. Barr.

demonstrated that the erythroblastic function became exhausted following a certain degree of hyperfunction".

According to Levi¹³, although the etiology of aplastic anemia is declared still obscure, it has been observed that the majority of cases occur in young, anemic, poorly nourished individuals who have lived in unhygienic environment, or in women who have suffered from repeated hemorrhages during pregnancy and in the puerperal state, or in individuals suffering from Syphilis, or alcoholism, or infections of a toxic nature, and thus, may cause degeneration of the bone marrow, which becomes a-regenerative, or as it is called, aplastic.

Lambri's¹² conclusions are that all etiological factors hitherto assigned as a cause may, in his opinion, be divided into two classes namely, toxic (chronic intoxicating infections, et cetera), and hormonal dysfunction or dys-equilibrium. Concerning the former, it is believed that the same toxic substance may, at times, act directly by inhibiting the hemopoietic function of the bone marrow (aplastic anemia). At other times it may attack and destroy the red corpuscles as they are about to enter into the circulation (pseudo-aplastic anemia of Biermer), and at still other times it may attack red corpuscles already in the circulation. With regard to the latter, attention is called to the hormonal relations which exist between the endocrine glands and morphological elements in the blood and in hemopoietic tissues. Chlorosis

IDIOPATHIC APLASTIC ANEMIA

by
L.C. Barr.

is excited as an example of the consequences of dysfunction of an endocrine gland (the ovary). In this connection, it is assumed that blood serum contains definite substances quite similar to or precisely identical with hormones, and capable of chemical stimulation of the regenerative function of the bone marrow; and that these substances are in turn the product of excretion of the elements of the blood which have been already referred to. Thus it appears evident that hematic insufficiency in an endocrinological sense may lead to aplastic anemia.

Rennie²¹ suggests that aplastic anemia occurs in the case of persons whose bone marrow is already in a state of potential failure owing to a congenital defect..

Quoting Herz⁹, who diagnosed a case of chloroma which was associated with aplastic anemia:

"Aplastic or a-regenerative anemias are biological variations of any kind of anemia. The causes vary. There are very acute forms in which the marrow has no time for changing. A-regenerative anemia is observed in septic processes and in serious hemorrhages. Benjamin likewise, considers it pathogenetically as a collective term for various diseases".

Stransky²⁸ believes that the "primary insufficiency of the blood forming apparatus is the cause of the clinical symptoms. In case of transfusion, the added quantity of

IDIOPATHIC APLASTIC ANEMIA

by
L.C. Barr.

blood must not produce an effect as such only, but the circulatory secretions of the glands with the internal secretions must also play apart. These probably are quickly decomposed and used up, and therefore no permanent effect results. There is much to be said for the assumption that in a-regenerative anemia in young children the cause is to be looked for not only in the anatomically indicated insufficiency of the blood-forming apparatus, but also in the lack of its modification through internal secretions or ferments. The severe disturbance and mental development support this assumption".

IDIOPATHIC APLASTIC ANEMIA

by
L.C. Barr.

V-MORBID ANATOMY.

Mead¹⁴ states that, at necropsy the typical case of aplastic anemia shows bone marrow which is yellow, fatty, or gelatinous gray, with few normal cell elements or none at all. Since it is inconceivable that any toxic or degenerative change can render the entire bone marrow completely aplastic at one time, it follows that the finding of a few small foci of normal or even hyperplastic marrow would not be incompatible with such a diagnosis. Other organs show consistent or significant changes other than those incidental to extreme anemia. Such large deposits of hemosiderin in the liver as Smith²⁶ observed in his case are not in accord with findings of most pathologists who, therefore, do not accept these isolated instances as evidence of a hemolytic nature in this anemia. Minot⁶ states that such a finding is not usually the case due to evidence, as diminished amounts of blood derived pigment in the excreta and plasma, absence of microcytes and enlargement of the spleen, indicates that this is not the case, and the presence of hemosiderin can be explained by hemorrhage and in other ways. There also may be a group of idiopathic hemolytic anemias which terminate in aplasia.

IDIOPATHIC APLASTIC ANEMIA.

L.C.^{by} Barr.

VI-SYMPTOMS.

Minot⁶ states that the onset is usually insidious and is marked by no particular symptoms except those referable to anemia, weakness or indefinite malaise, and pallor, and the symptoms increase as the anemia progresses. There often is a history of the patient not having felt strong or well for some weeks or months before the definite symptoms develop from which the beginning is dated. Possibly there may be a history of infection preceding the symptoms or perhaps the patient has never been strong. This latter type of history is, perhaps, not rare in various essential blood disorders, and as stated by Rennie²¹ might suggest that a congenital weakness of the hemopoietic function at times played a part in the production of such a disease. Noland's¹⁸ observations are that fever may occur. At times it may be quite marked and suggestive of Typhoid Fever. Purpuric manifestations nearly always occur and are proportionate in severity to the decrease in platelet count. When the platelets are predominately decreased all the evidences of a symptomatic purpura hemorrhagica may be present.

Duke's⁵ conclusions as to the symptoms displayed by a patient with aplastic anemia depend on which of the formed elements of the blood are most markedly reduced, If red cell reduction predominates the situation, anemia is the prominent symptom. If the granulocytic element is the most markedly

IDIOPATHIC APLASTIC ANEMIA.

by
L.C. Barr.

involved, the prominent symptom is like to be infection. If the platelets are involved, bruises and a tendency to bleed from trivial abrasions may be the only hemorrhagic symptoms. The foregoing statements apply to the cases in which aplasia of the marrow is the sole factor of importance. In some cases however, another element is important; namely, destruction of the blood in circulation. Apparently, in many instances, the agent that injures the marrow also tends to destroy the formed elements in the blood itself. When this is the case, symptoms of blood destruction may be added to those previously mentioned so that there may be in addition poikilocytosis, fever, accumulation or excretion of derivatives of blood pigment and enlargement of the liver or spleen. This may give rise to the red cell picture resembling that of pernicious anemia rather than that of a secondary anemia. The whole symptom complex differs strikingly, however, from that of a typical pernicious anemia in the absence of such symptoms as stomatitis, atrophy of the papillae of the tongue, and other tissues, neuropathies, marked increase in the color index of the red cells, macrocytosis, and achylia.

Warr³² states that even so simple a procedure as the extraction of a tooth may, when there is great reduction of granulocytes, start up a rapidly fatal general infection or in case there was a great reduction in platelets, profuse hemorrhage would occur.

IDIOPATHIC APLASTIC ANEMIA.

by
L.C. Barr.

VII-Physical Examination and Laboratory.

Briefly the physical examination reveals little except a patient in a general weakened anemic condition and according to Minot¹⁶ the patient appears pale, (white pallor) and at times it is a trifle waxy. The sclerae are a dead white in color and never yellowish. Commonly purpuric spots may be found or hemorrhage from the mucous membrane, or perhaps extensive necrosis of a mucous membrane. The laboratory findings as given by Minot¹⁶ are very impressive especially the blood picture which shows no or very little evidence of regeneration of the three formal elements originating in the marrow: (a) the red blood cells usually drop to a million or below before death; the cells appear quite well filled with hemoglobin and the color index is but slightly reduced. There is little or no variation in the shape and relatively little variation in the size particularly when one considers the degree of anemia. Polychromatophilia, stippling and nucleated cells are usually absent or rare. The reticulated cells are commonly diminished or even absent, though at times transient increases above their normal percent may occur, dependent upon the remaining tissue putting forth what young cells it can.

(e) The white blood cells always show a leukopenia,

IDIOPATHIC APLASTIC ANEMIA.

by
L.C. Barr.

more marked as the disease progresses. Lenkopenia consists in an absolute diminution of the polynuclear cells and nearly always there occurs a disappearance of the eosinophiles. Thus a relative but not absolute lymphocytosis occurs, the lymphocytes being, at the time the anemia is well marked about seventy percent of the white blood cells. They are of the small type. Atypical and abortive polynuclears are apt to be seen, and granular mononuclears are rather often increased, particularly when the process is not far advanced, but distinctly early bone marrow white cells, like myeloblasts are exceedingly rare. (c) The platelets are markedly decreased, often nearly absent. They are usually slightly larger than normal. The platelets are not so decreased early in the disease. Further evidence of aplasia is seen in the absence of any response on the part of the marrow to transfusion.

The fragility of red cells to salt solution is abnormal and of the following type: the cells begin to break up in about the same strength as they normally do, not infrequently in a weaker solution, but complete hemolysis occurs in a higher percentage of salt solution than normal. This type of fragility is to be looked upon as an undesirable one. It may occur in other conditions, as simple severe depression of hyperplastic marrow and in some cases of idiopathic purpura hemorrhagica.

Mead¹⁴ states that the "characteristic clotting phenomena

IDIOPATHIC APLASTIC ANEMIA

by
L.C. Barr.

which accompanys any marked platelet reduction are found in this disease,----a prolonged bleeding time, normal or slightly delayed coagulation time, and a non-retractile clot.

According to Ordway and Gorham¹⁹, the free hydrochloric acid of the gastric juice is normal or only slightly reduced. Urobilin is increased only if there is evidence of extensive hemorrhage into the tissues.

Smith²⁶ reports in his summary, the hemoglobin average in thirty-three cases was 17%, or the highest was 35%, and the lowest 10%. The average number of red cells in forty-seven cases was one million, the lowest two-hundred thousand, and the highest two-million-two-hundred-thousand. The average white blood cell count in forty-four cases was three thousand; the highest was forty-thousand and the lowest two-hundred-fifty.

IDIOPATHIC APLASTIC ANEMIA
by
L.C. Barr.

VIII-DIAGNOSIS.

According to Duke⁵, "Aplastic anemia is a disease which is rarely observed by the general practitioner". As a type of anemia, however, it is relatively common and very important. It is often overlooked or misdiagnosed because of its varied and striking manifestations, which frequently mask completely the primary illness and cause it to be classed with other diseases, such as infectious or hemorrhagic diseases.

The absolute diagnosis cannot be made without the examination of the bone marrow which shows a typical aplastic condition. Repeated blood examinations with a marked anemia, without evidence of normoblasts, anisocytosis nor poikilocytosis, a leucopenia with a relative lymphocytosis, and the diminished platelet count will suggest aplastic anemia.

The commoner confusing diseases which will require differentiation are, according to Carey and Taylor²:

1-Pernicious anemia; the history is usually of longer duration and contains references to gastro-intestinal symptoms, an achlorhydria, paraesthesias, and glossitis. It usually occurs later in life. There are evidences of hemolysis, usually, into the skin, urine, duodenal contents, blood serum, and feces. The anemia is not so profound until the end stages, nor are the hemorrhagic features prominent, although often present. The platelet count is usually not

IDIOPATHIC APLASTIC ANEMIA

by
L.C. Barr.

so reduced, nor is there such a marked leukopenia. The anemia is of the hyperchrome type. The bone marrow shows hyperplasia.

2-In thrombocytopenic purpura, the hemorrhagic features are more marked, and the anemia and the leukopenia less so than in aplastic anemia. The morphology of the blood elements is practically normal. There is a red cellular marrow with an increase of blood elements and a decrease of fat.

3-Agranulocytic angina is a condition in which a severe gangrenous stomatitis develops and is accompanied by a blood picture of complete or almost complete absence of granular leukocytes. The red blood count and the hemoglobin may remain within normal range. The patients are usually middle aged and females, There are usually no hemorrhagic features. The bone marrow in this condition shows no characteristic changes of the red cell elements, but the granular cells are absent.

4-The aleukemic phase of a leukemia simulates aplastic anemia except for the fact that in the former, miniature cells of the lymphocyte group commonly reach the peripheral circulation, while in aplastic anemia, practically all the lymphocytic cells are of the mature small lymphocyte variety. Ruling out pernicious anemia, purpura hemorrhagica, aleukemic leukemia, and agranulocytic angina, one must still

IDIOPATHIC APLASTIC ANEMIA

by

L.C. Barr.

think of the possibility of bone marrow tumors as multiple myelomata, easily distinguished by the x-ray, or hemophilia, where the number of blood platelets is normal"---

Mead¹⁴.

IDIOPATHIC APLASTIC ANEMIA

by
L.C. Barr.

IX-PROGNOSIS.

According to Duke⁵ aplastic anemia is an illness which must always be taken seriously. The gravity of the condition depends naturally on the primary cause of the disorder and on the degree of the reduction in the formed elements of the blood. For this reason the prognosis varies. In highly aplastic cases of unknown origin the outlook is extremely bad. The illness^{is} almost certain to terminate fatally, within a period of a few days, weeks, or months. If the primary cause of the aplasia is known and can be removed, there is a good chance for recovery, but the idiopathic type is practically always fatal early.

IDIOPATHIC APLASTIC ANEMIA

by
L.C. Barr.

X-TREATMENT.

Usually the condition of aplastic anemia is not diagnosed until it is rather far advanced and any known treatment is practically of little avail. Perhaps if the case were diagnosed earlier, the different types of treatment might be more valuable.

Gibson⁸ recommends daily subcutaneous injections of adrenalin and blood transfusion. He treated a patient--female age 11, with a rather typical picture of severe idiopathic aplastic anemia. He states that the beginning of recovery coincides with the giving of the adrenalin. The patient recovered completely.

Fleming's results of the following treatment in a patient 26 years old--female:

- 1-Transfusion gave temporary relief.
- 2-Iron and arsenic over long periods gave no benefit.
- 3-Extract of bone marrow of no value.
- 4-X-ray over chest bones (4 exposures) caused a serious drop in the number of red cells--patient died.
- 5-Oxygen inhalations proved serviceable.

Jackson, Parker, Rinehart, and Taylor¹¹ in their "STUDIES OF DISEASES OF THE LYMPHOID AND MYELOID TISSUES", found that nucleotides may have a definitely favorable effect on an inactive bone marrow in certain cases of malignant

IDIOPATHIC APLASTIC ANEMIA

L.C.^{by} Barr.

neutropenia. They state that the marked change is a granulocytosis, and perhaps in a marked aplastic anemia there might be a favorable reaction.

In 1929 Upham and Nelson³¹ reported a case--male 21 years of age--of primary aplastic anemia treated with massive doses of fetal liver and repeated transfusions. The feeding of fetal liver caused a coincident increase of reticulocytes. The patient has been under careful management for two years and at the time of editing the article, they state that he was far from recovery but they felt encouraged at the good response.

Duke's⁵ states that, "treatment should be directed primarily toward removal of the cause of the aplasia, if the cause can be found and if it can be removed. Diet is of less service in this type of anemia than in pernicious anemia unless definite dietary deficiency is found to be the true cause of the disorder. Transfusion is very useful for the purpose of restoring either red cells or platelets. If adequately given, it relieves the symptoms of anemia or of purpura hemorrhagica. In the case of purpura hemorrhagica, it may be necessary to repeat transfusion at intervals of from three to five days because of the natural short life of the blood platelets. The onset of infection is a serious complication and is likely to terminate fatally if once started. Because of the high grade loss of resistance to

IDIOPATHIC APLASTIC ANEMIA

by
L.C. Barr.

infection, the traumatizing of small infections should be carefully avoided. If pyorrhea is found, for example, it should be treated with mild modification rather than by instrumentation, and tonsils if infected should be treated medically or left alone. Surgery should by all means be postponed. Furthermore, the traumatization of membranes such as the nasal or uterine mucous membranes by packing, to control hemorrhage may have a disastrous sequence in the form of hemorrhage or of local, followed by general infection, or of all combined".

Mills¹⁵ of Canada used a capsule three times a day, which contained Blaud's mass grams 2, copper sulphate mgms. 1.5 and cascara grams 0.2. In a series of ten cases of this disease so treated, prompt improvement followed in all cases with restoration of the blood to about its normal level.

IDIOPATHIC APLASTIC ANEMIA
by
L.C. Barr.

XI-Summary and Conclusions.

1. Aplastic anemia is a symptom complex and not a separate disease entity.

2. It is a condition in which all the blood elements are greatly reduced due to lack of regeneration within the bone marrow and an aplasia of these tissues occur.

3. Erhlich in 1888 recognized and reported the first case and since then, about one-hundred-fifty cases which fit into the group in which the etiology is unknown have been reported.

4. This condition more commonly occurs in young adults between twenty and thirty years and possibly it is slightly more common in the female.

5. The symptoms which will be present depend on which blood element is most severely damaged; weakness, tingling and pallor, in case it is the red cell, purpura, in case of the platelets, or infection, if the white cells are reduced to a greater proportion.

6. Aplastic anemia may be due to a recognized cause such as a sever infection, metallic or organic poisoning, radium or excess x-ray irradiation, alcohol, intestinal parasites, neoplasms, endocrine disturbance, pregnancy, toxemia, defective diet et cetera. Aplastic anemia may also occur in which there is no recognized cause. Various

IDIOPATHIC APLASTIC ANEMIA

by
L.C. Barr.

theories as to the possible cause are:

- (a). Levi believes that constitutional inadequacy plays a part, since the majority of cases occur in young, anemic, poorly nourished individuals who have lived in an unhygienic environment or in people who have suffered severe physiological strains.
- (b). Lambri believes there may be an endocrine imbalance. He suggests that normally the hormone may be responsible to stimulate the regenerative function of the bone marrow.
- (c). Stransky believes a combination is responsible or an insufficiency of the blood forming apparatus and a deficiency of an internal secretion or ferment.
- (d). Rennie's opinion is that the state of potential failure is due to a congenital defect.

7. The absolute diagnosis is based upon an examination of the bone marrow with characteristic aplasia. A tentative diagnosis may be made on the laboratory findings, in which there is a great deficiency of all the elements of the blood stream; no or very few normoblastic cells are found; little or no anisocytosis nor poikilocytosis; there is a relative lymphocytosis with a great decrease of the granulocytes; no response on the part of the marrow to transfusion; prolonged bleeding time, normal coagulation, and a non-retractile clot.

IDIOPATHIC APLASTIC ANEMIA

by
L.C. Barr.

Various conditions as pernicious anemia, purpura hemorrhagica, aleukemic leukemia, agranulocytic angina, or a multiple myelomata must be differentiated.

8. The prognosis in the case the cause cannot be discovered and removed is usually fatal.

9. The treatment is;

- (a) Attempt to find the cause and remove it.
- (b) Gibson had excellent results in one case with the subcutaneous injection of adrenalin.
- (c) Upham and Nelson recommend massive doses of fetal liver, and transfusions.
- (d) Mills recommends copper and iron.

10. The case reported is one of aplastic anemia of unknown etiology. The laboratory and autopsy findings are characteristic. The purpuric symptoms were more pronounced early, indicating a more severe platelet damage and as stated by Marr, even an extraction of a tooth may be an explosive factor.

CONCLUSIONS:

1. Aplastic anemia is an anemia secondary to marrow changes which in turn is dependent on some known or unknown cause.
2. Aplastic anemia probably occurs much more frequently than reported.
3. Extensive laboratory work should always be done in every blood disorder, and in case a hypoplastic or an aplastic condition

IDIOPATHIC APLASTIC ANEMIA
by
L.C. Barr.

is indicated, good hygienic care, proper diet, and treatment should be instituted early.

IDIOPATHIC APLASTIC ANEMIA.

by
L.C. Barr.

XII-BIBLIOGRAPHY.

1. Agnew, G.H., Idiopathic Aplastic Anemia. Canadian Med. Ass. Jour., Sept. 1921, 14:859-861
2. Carey, J.B. and Taylor, J.H. Primary Aplastic Anemia. Ann. Int. Med., Oct. 1931. 5:471-472.
3. Doan, C.A., The Capillaries of the Bone Marrow of the Adult Pigeon. Johns Hopkins Hosp. Bull., 1922. 33:222-226.
4. Duke, W.W., Bone Marrow. Int. Med., Jan. 1930. 11:100.
5. Duke, W.W., Aplastic Anemia, Jour. A.M.A. Sept 8, 1928. 91:720-722.
6. Ehrlich, P., Charite Annaleus, Berl., 1888, 13:300-309.
7. Frank, Abstract. Berlin, Klin, Woch., 1916. 37:page.
8. Gibson, A.G., The Action of Adrenalin in Aplastic Anemia. Lancet, Nov., 1926. 948-949.
9. Herz, C., Aplastic Anemia and Chloroma. Abstract. Munchener Medizinische Wochenschrift. May 21, 1926. 73:868-869.
10. Hirschfeld, H., Uber Aplastic Anemia. Abstract. Folia Hematologica. 1911, 12:347-349.
11. Jackson, H. Jr., Parker, F., Rinehart, J., Taylor, F.. Studies of Diseases of the Lymphoid and Myeloid Tissues. Jour. A.M.A. Nov. 14, 1931. 97 pt 2:1436-1438.
12. Lambri, R., Aplastic Anemia, Extract, Morgagni, 1922. 64:150-152.
13. Levi, E., Osservazioni Cliniche sulla Anemia Aplastica, Abstract. Gazzeta degli ospedali. 1921, 42:487-490.
14. Mead, W.R., Aplastic Anemia. Jour. South Carolina Med. Assc. Sept. 1929, 25: 517-520.
15. Mills, E.S., The Treatment of Idiopathic Anemia with Iron and Copper. The Canadian Med. Assc. Journal. Feb. 1930. 22:175-178.
16. Minot, G.R., Aplastic Anemia. Oxford Medicine. II:605-611.

IDIOPATHIC Aplastic ANEMIA.

by
L.C. Barr.

17. Musser, J.H., Study of a Case of Aplastic Anemia. Arch. Int. Med., 1914. 14:275-288.
18. Noland, H.V., Fetal Liver Feeding in Aplastic Anemia. Kentucky Med. Jour.. July 1931. 29:340-342.
19. Ordway and Gorham: Oxford Monographs on Diagnosis and Treat. 9:219-242.
20. Pappenheim, A., Pathologie und Therapie der Hemorrhagischen diathesen und anamien. Folia Haematologica. 1905, 9:30-355.
21. Rennie, G.E., Aplastic Anemia. Med. J. Australia. 1919. 1:485.
22. Root, J.H., Idiopathic Aplastic Anemia. The New Eng. Jour. of Med.. Dec.18, 1930. 1225-1228.
23. Sabin, F.R., Bone Marrow. Physiological Reviews. 1928, 8:191-194.
24. Schneider, J.P., Aplastic Anemia. Am. Jour. Med. Sc., 1918, 156, 799
25. Scheard, J., Monograph on Pernicious Anemia and Aplastic Anemia. Wm. Wood and Co., New York. 1924.
26. Smith, L.W., Unusual Cases of Aplastic Anemia. Am. J. of Diseases of Children. 1919, 17:174-176.
27. Stone, W.J., So-called Aplastic Anemia and its Relation to Progressive Pernicious Anemia. Ohio State Med. J. November, 1907.
28. Stransky, E., Clinical Hematology of Infants. A-regenerative Anemia in Young Children. Abstract. Zeitschrift fur Kinderheilkunde. 1925, 39:553-568.
29. Symmers, D., Primary Progressive Pernicious Anemia and Aplastic Anemia. Interst. Med. Jour. 1917, 24:1103-1108.
30. Turk, W., Haemolytische anaemien mit mangelhafter oder fehlender markeaktion (Aplastische haemolytische anaemien). Vorle-Sungen Uber klinische Haematologie , W. Braunmuller, Wien 1912, 740. Abstract.
31. Upham and Nelson, Fetal Liver Feeding in Aplastic Anemia. J. Missouri Med. Assc. Jan. 1930. 27:1-5.
32. Warr, O.S., Aplastic Anemia. J.A.M.A. Sep. 8, 1928. 722.
33. University of Nebr. Hospital Records.

RECEIVED
UNIVERSITY OF NEBRASKA
APR 1 1932
OFFICE OF THE DEAN
COLLEGE OF MEDICINE